

Single Case

Congenital Internal Hernia: Rare Cause of Acute Abdominal Pain

Jay Patel Antoine Hamedi Muhammad Khalil Jessica El-Bahri

Department of Internal Medicine, Orange Park Medical Center, Orange Park, FL, USA

Keywords

Internal hernia · Abdominal pain · Obstruction

Abstract

Acute abdominal pain is a common presenting symptom that possesses a wide differential. Congenital internal hernias are a rare condition that often presents with abdominal pain and can lead to obstruction. Early diagnosis is often difficult and therefore can present acutely and in an emergent setting. Prompt recognition of symptoms and evaluation are important to prevent poor prognosis. We are presenting a case of a congenital internal hernia in a patient presenting with nonspecific symptoms. Prompt diagnosis and subsequent surgical intervention allowed for appropriate management and resolution of symptoms.

© 2021 The Author(s).

Published by S. Karger AG, Basel

Introduction

Although internal hernias are uncommon, they must always be considered in the differential diagnosis of acute abdominal pain. Because of the high possibility of strangulation and ischemia, IH represents a potential surgical emergency that needs to be quickly recognized and managed promptly. According to various investigators, internal hernias cause up to 5.8% of all small bowel obstruction (SBO), with a high overall mortality rate that can exceed 50% [1]. Preoperative suspicion and diagnosis in an emergency setting are difficult due to rarity of the entity, nonspecific clinical presentation, and limited utility of imaging in cases of acute intestinal obstruction [2]. Here, we describe a primary transmesenteric internal hernia in a 29-year-old male who presented with nonspecific symptoms and whose concurrent median arcuate ligament compression made diagnosis challenging.

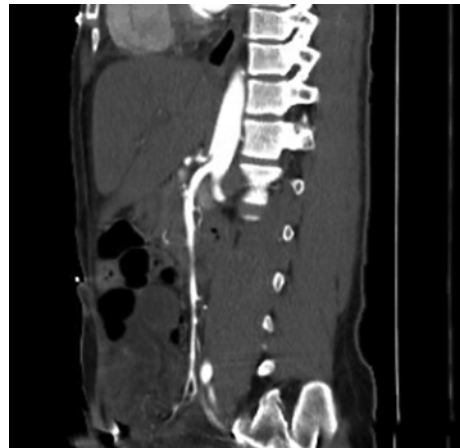


Fig. 1. CT scan of the abdomen and pelvis with intravenous contrast demonstrating mild compression of the celiac artery.

Case Presentation

A 29-year-old male with no past medical history presented with complaints of acute onset lower back pain with radiation to the lower abdomen. On examination, vital signs were stable and the patient appeared in no acute distress. He endorsed mild tenderness to palpation of the lower abdomen, but no rebound or guarding was appreciated. Computed topography (CT) scan with intravenous contrast of the abdomen and pelvis indicated possible medial arcuate ligament (MALS) compression of celiac artery (shown in Fig. 1). The surgical team was consulted and they suspected median arcuate ligament syndrome and recommended arteriographic evaluation of the celiac artery. The patient was transferred to the catheterization laboratory to image his celiac artery; however, the patient's pain acutely worsened and abdomen distended. Despite fluid administration, lactic acid continued to elevate to above 3. He was taken to the operating room for an immediate exploratory laparotomy. A loop of distal jejunum to distal ileum was found to be strangulated through a defect in the patient's mesentery. This small bowel transmesenteric hernia was noted to be gangrenous and 320 cm of small bowel was excised (shown in Fig. 2). Postoperative recovery was uneventful and the patient was discharged on the sixth postoperative day. He is now on follow-up and is doing well after surgery with no symptoms.

Discussion

Acute abdominal pain is a common presentation that encompasses a broad differential. Internal hernias, although uncommon, represent an important differential that must be kept in mind, as they can quickly progress to become life-threatening.

Internal hernias occur when abdominal organs, typically the intestines, protrude through the mesentery or peritoneum, but remains within the abdominal cavity [3]. They are a rare cause of acute abdominal pain, found on autopsies of suspected patients <1% of the time, and being found as the cause of SBO <6% of the time [4]. Transmesenteric hernias are a subset of internal hernias in which both layers of the small bowel hernia through inherent defect in the mesentery [1]. This defect can either be congenital or acquired, with acquired being more common, occurring typically after surgery. Congenital hernias, although more common in children, can occur at any age [5]. They represent a rare cause of SBO, with one paper reporting only 13 adult case reports [6, 7]. Due to the patient's lack of prior surgeries or trauma, his



Fig. 2. 320 cm of resected necrotic bowel.

hernia was likely congenital in nature. MALS was likely an incidental finding not contributing to his acute presentation and initially diverted focus.

Our patient had a nonspecific presentation. After its appearance on imaging, MALS was initially the focus of management, especially with the patient's nontoxic appearance. However, with an acute worsening of his abdominal pain, distention, and increasing lactic acid, the appropriate decision was made to proceed with surgery. Prevention of confirmation bias is crucial, and being open-minded and using progressive objective findings can help with diagnosis. Any further delay in diagnosis may have prevented appropriate management of his internal hernia, leading to enhanced rates of ischemia and gangrene [3].

Our patient did not have any prior trauma or surgical history suggestive of acquired internal hernia. Presenting symptoms were quite nonspecific, with vague abdominal pain and unremarkable rest of the exam. Initial imaging indicated evidence of SBO and possible MALS, without any indication for any emergent acute process.

Lack of specific laboratory or imaging makes evaluation and diagnosis of internal hernias challenging. CT remains the modality of choice for initial workup of abdominal pain. However, questions remain over its utility in the acute setting. The patient's initial exam and vital signs did not reflect acute emergency. With the abrupt worsening of clinical status, presence of free pelvic fluid and worsening lactic acidosis, surgical intervention was necessary.

Acute abdominal pain presents with a wide differential, with congenital internal hernia presenting as a very rare cause. It should always be on the differential, particularly in the setting of nonspecific initial workup and worsening clinical findings.

Acknowledgements

This manuscript does not include any nonauthor contributors to acknowledge.

Statement of Ethics

This paper was reviewed and approved by HCA Pubclear, ethics approval was not required. Written informed consent was obtained from the patient for publication of this case report and any accompanying images.

Conflict of Interest Statement

The authors of this manuscript do not have any conflict of interest to declare.

Funding Sources

This research was supported (in whole or in part) by HCA Healthcare and/or an HCA Healthcare affiliated entity. The views expressed in this publication represent those of the author(s) and do not necessarily represent the official views of HCA Healthcare or any of its affiliated entities.

Author Contributions

El-Bahri, Hamed, and Khalil conceived the project. Patel, Hamed, Khalil, and El-Bahri all played a role in literature review, write up, and review of article. Patel is serving as corresponding author in regards to submission.

Data Availability Statement

All data generated or analyzed during this study are included in this article [and/or] its online suppl. material files; for all online suppl. material, see www.karger.com/doi/10.1159/000518293. Further enquiries can be directed to the corresponding author.

References

- 1 Lanzetta MM, Masserelli A, Addeo G, Cozzi D, Maggioletti N, Danti G, et al. Internal hernias: a difficult diagnostic challenge. Review of CT signs and clinical findings. *Acta Biomed*. 2019 Apr 24;90(Suppl 5):20–37.
- 2 Ghiassi S, Nguyen SQ, Divino CM, Byrn JC, Schlager A. Internal hernias: clinical findings, management, and outcomes in 49 nonbariatric cases. *J Gastrointest Surg*. 2007 Mar;11(3):291–5.
- 3 Kar S, Mohapatra V, Rath PK. A rare type of primary internal hernia causing small intestinal obstruction. *Case Rep Surg*. 2016 Nov;2016:3540794–3.
- 4 Jang EJ, Cho SH, Kim DD. A case of small bowel obstruction due to a paracecal hernia. *J Korean Soc Coloproctol*. 2011;27(1):41–3.
- 5 Gyedu A, Damah M, Baidoo PK, Yorke J. Congenital transmesenteric defect causing bowel strangulation in an adult. *Hernia*. 2010;14(6):643–5.
- 6 Butterworth J, Cross T, Butterworth W, Mousa P, Thomas S. Transmesenteric hernia: a rare cause of bowel ischaemia in adults. *Int J Surg Case Rep*. 2013;4(7):568–70.
- 7 Blachar A, Barnes S, Adam SZ, Levy G, Weinstein I, Precler R, et al. Radiologists' performance in the diagnosis of acute intestinal ischemia, using MDCT and specific CT findings, using a variety of CT protocols. *Emerg Radiol*. 2011;18(5):385–94.